

Characterization of DHEA-induced PCOS-model by CARS Microscopy

L. Fésűs^{1,2}, D. Domokos⁴, V. Lener⁴, T. Jakabovics⁴, R. Szipőcs^{2,3,*}, A. Kolonics^{3,4}

¹Department of Dermatology, Semmelweis University, Budapest, Hungary

²Institute for Solid State Physics and Optics of Wigner RCP, P.O. Box 49, H-1525 Budapest, Hungary

³R&D Ultrafast Lasers Ltd, P.O. Box 622, H-1539 Budapest, Hungary

⁴BioFirmware Ltd, Berliini st. 47-49, H-1045 Budapest, Hungary

* r.szipocs@szipocs.com

Abstract: The efficiency of *Origanum majorana* and *Mentha piperita* essential oil co-treatment was studied on DHEA-induced PCOS-model by analysis of lipid content changes in cumulus oocytes complexes by CARS and Bodipy fluorescence microscopy. © 2019 The Author(s)

OCIS codes: (170.3880) Medical and biological imaging, (180.4315) Nonlinear microscopy.

1. Introduction

Polycystic ovary syndrome (PCOS) is one of most frequent female endocrine disorder, affecting 5%–10% of women, causing infertility, dysfunctional follicular maturation and ovulation, multicystic ovaries, hyperandrogenism. PCOS play a role in the enhancement of the risk of cardiovascular diseases and the development of diabetes [1]. Postnatal treatment of rodents with DHEA (Dehydroepiandrosterone) induced human PCOS characteristics of acyclicity, anovulation, polycystic ovaries, and hyperandrogenism: DHEA induces ovarian cysts and causes abnormal hormone level (increased serum testosterone, androstenedione and 5- α -dihydrotestosterone) similar to the women with PCOS [2]. Development of cysts causes an alteration of ovarian function and an imbalance in the oxidant–antioxidant balance [3]. Increased ROS within ovarian cells is associated with the impaired ovarian function [4]. DHEA transformed into potent estrogens such as estradiol and produces estrogenic effects of female sex hormone. Estradiol is involved in the regulation of the female reproductive cycles and responsible for the development of female secondary sexual characteristics such as the breasts, widening of the hips, and a feminine pattern of fat distribution in women. Mouse cumulus oocyte complexes (COCs) exhibit lipotoxicity responses in association with obesity or following treatment with high levels of *lipids in vitro* [5]. Traditional medicine, marjoram herb (*Origanum majorana*) tea was found to improve insulin sensitivity and reduce the levels of adrenal androgens in the hormonal profile of PCOS women in a randomised, double-blind, placebo-controlled trial [6]. Spearmint (*Mentha spicata*) has treatment potential on PCOS through inhibition of testosterone and restoration of follicular development in ovarian tissue) [7]. In our study we investigated the effects of pure 100 % natural essential oil mix of *Origanum majorana* and *Mentha piperita* in DHEA-induced PCOS-model by nonlinear microscopy.

2. Methods

4 week-old (~18 g) female C57 bl/6 mice (KinetoLab, Budapest, Hungary) were kept at 22 ± 2 °C under a 12 h light/12 h darkness cycle. The animals were fed normal diet and water was available *ad libidum*. C57BL/6 female mice were treated with dehydroepiandrosteron (DHEA) daily (6 mg/100 g body weight in 0,1 ml oil subcutan) for 20 consecutive days. The DHEA treated animals were randomized into different treatment groups (n=6). DHEA-K group and DHEA + Essential oil mix group. The latter group, after a DHEA treatment, was subsequently treated *per os* for 10 consecutive days with water solution of *Origanum majorana* (150 mg/kg^{body mass}, CAS 84082-58-6, Silvestris Ltd., Hungary) and *Mentha piperita* (20 mg/kg^{body mass}, CAS 8006-90-4, Azelis Ltd., Hungary) essential oils. After 20 days DHEA and 10 days Essential oil mix treatment, the mice were injected intraperitoneally (i.p.) with PMSG (pregnant mare's serum) at 5 IU/12 g of body weight, followed 48 h later by i.p. injection of hCG (human chorionic gonadotropin) at 5 IU/12 g of body weight. The ovaries were dissected and COCs were isolated from the oviducts at 16 h after hCG injection, placed in HEPES-buffered α -MEM (5 % FBS) and counted under microscope. The COCs were stained by Bodipy (Sigma-Aldrich) for lipid content or by MitoSOX Red (ThermoFischer Scientific), which is a mitochondrial superoxide indicator. During the staining procedure manufacturer's instructions was followed. After washing steps the COCs were fixed by paraformaldehyde. We used a 2PEF and CARS imaging setup similar to that was reported in Ref. 8. For CARS-lipid imaging, we applied the CH₂ stretching frequency of 2845 cm⁻¹, for which the laser central wavelength was set to 800 nm in order to minimize the unwanted excitation of proteins. Note that our Stokes laser operates at 1030 nm [8]. For detections of

the 2PEF signal of the two different fluorescent labelling, two bandpass filters with green (500-550 nm, Bodipy) and orange (565-610 nm, MitoSOX Red) transmission bands were used.

3. Results

As a first step, we checked the co-localization of *Bodipy* fluorescent labelling and the detected CARS-lipid signal (see Fig.1). We found that even the small lipid droplets in the cells are clearly seen in both pictures. Interestingly, the CARS image shows slightly higher spatial resolution than the 2PEF image. As a next step, we compared the DHEA-induced changes of lipid content and ROS-level in COCs of murine PCOS-model by label-free CARS and MitoSox Red-labelled 2PE fluorescence microscopy (see Fig. 2). We found that DHEA treatment of female mice results in elevated lipid concentration of COCs parallel with increased mitochondrial ROS-production. Essential oil-mix treatment of mice decreased lipid and mitochondrial ROS-level in COCs.

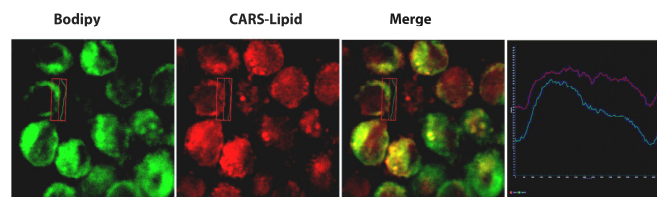


Fig.1. Bodipy staining is concentrated mainly into the cytosol, which shows a clear co-localization with the detected CARS-lipid signal. Interestingly, the CARS image shows slightly higher spatial resolution than the corresponding 2PEF image.

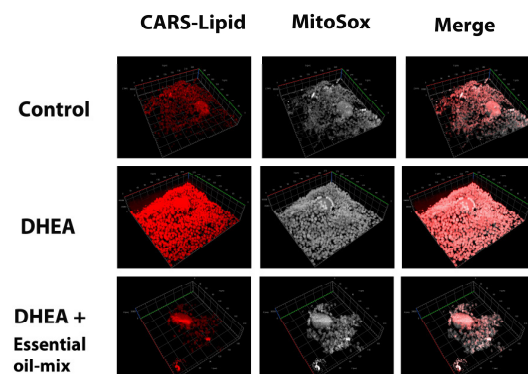


Fig. 2. Comparison of DHEA-induced changes of lipid content and ROS-level in COCs of murine PCOS-model by label-free CARS and MitoSox Red-labelled 2PE fluorescence microscopy.

Concluding our results we can say that an increased dose of DHEA treatment resulted in PCOS escorted with elevated abdominal adipose tissue and liver weight (data not shown here) parallel with increased lipid-levels in COCs and elevated ROS-production. Essential oil-mix treatment resulted in decreased level of lipid and ROS in the cells. Label-free CARS imaging has been found to be a good alternative for Bodipy staining of lipids. Accordingly, CARS imaging might be a plausible approach to examine the effects of drugs on murine PCOS DHEA-model.

4. References

- [1] D.H. Abott, et al. „Developmental origin of polycystic ovary syndrome-a hypothesis.,” *J Endocrinology*,. **174**, 1-5 (2002).
- [2] V. Sander, et al. „Role of the N, N'-dimethylbiguanide metformin in the treatment of female prepubertal BALB/c mice hyperandrogenized with dehydroepiandrosterone,” *Reproduction* **131**, 591-602 (2006).
- [3] C.G. Luchetti, et al. „Effects of dehydroepiandrosterone on ovarian cystogenesis and immune function,” *J Reproductive Immunology*. **64**, 59-74. (2004).
- [4] A.B. Motta, et al. „The involvement of nitric oxide in corpus luteum regression in the rat: feedback mechanism between prostaglandin F2a and nitric oxide,” *Molecular Human Reproduction*,. **5**, 1011-1016 (1999).
- [5] L.L. Wu, et al., „High-fat diet causes lipotoxicity responses in cumulusoocyte complexes and decreased fertilization rates,” *Endocrinology* **151**, 5438-5445 (2010).
- [6] L. Haj-Husein, et al. „The effect of marjoram (*Origanum majorana*) tea on the hormonal profile of women with polycystic ovary syndrome: a randomised controlled pilot study,” *J Human Nutrition Diet* **29**, 105-111 (2016).
- [7] A.M. Sadeghi, et al. „Role of Essential Oil of *Mentha Spicata* (Spearmint) in Addressing Reverse Hormonal and Folliculogenesis Disturbances in a Polycystic Ovarian Syndrome in a Rat Model,” *Adv. Pharm. Bull.* **7**, 651-654 (2017).
- [8] D. Haluszka, K. Lőrincz, N. Kiss, R. Szipőcs, E. Kuroli, N. Gyöngyösi, and N. Wikonkál, “Diet-induced obesity skin changes monitored by in vivo SHG and ex vivo CARS microscopy,” *Biomed. Opt. Express* **7**, 4480–4489 (2016).